

DO COLOR DUPLEX AND POWER DOPPLER SONOGRAPHY INCREASE THE DETECTION RATE OF PROSTATE CANCER?

By

Azmy Mohammed Omar*, Shehata Hasan Farghal**,
Shawky Abd Elazeem Elmikkawy** and Khaled Fathy Elewa*

*National Institute of Urology and Nephrology, Cairo

**Urology Department, Al-Azhar Faculty of Medicine, Cairo

ABSTRACT

Background: Although gray-scale Trans Rectal Ultrasonography (TRUS) was a major achievement in diagnosis of prostate cancer, it has several limitations. Expert users are not able to discriminate among images with more than 32 gray levels out of 256 displayed on a gray-scale image.

Objective: The aim of the study was using color and power doppler in targeting prostatic biopsy and detecting prostate cancer.

Patients and methods: This prospective study included 100 consecutive patients attended Al-Azhar University Hospitals and National Institute of Urology and Nephrology with lower urinary tract symptoms (LUTS), and have either Prostatic Specific Antigen (PSA) > 4 ng/ml or abnormal prostate on digital rectal examination (DRE). Patients with coagulopathy, history of prostate cancer diagnosis or evidence of a prostatic intraepithelial neoplasm of any grade were excluded. All patients were subjected to (DRE), International Prostatic Symptoms Score (IPSS), complete laboratory investigation including PSA, pelvi-abdominal ultrasound, gray-scale, color and power doppler TRUS, and TRUS-guided systematic biopsies with other focal lesion-targeted biopsies.

Results: Histopathological examination of cores taken from hypo-echoic lesions revealed adenocarcinoma in 24 cases: 6 out of them were of group (A), and 18 were of group (B). So, cancer was detected in 50 % (6/12) of hypo-echoic lesions in group (A), and in 64.3% (18/28) of group (B) which was statistically significant. Correlation between the cores taken from hyper-vascular areas and the results of histopathology revealed that cancer was detected in 38 (74.5%) out of 51 hyper-vascular areas (8 out of them were of group A, and 30 were of group B). So, the incidence of cancer detection in hyper-vascular areas in group B (83.3%) was higher than group A (53.3%) which was statistically significant.

Conclusion: The combination of color and power doppler ultrasound and gray-scale TRUS increased the sensitivity of detecting prostate cancer while not decreasing the specificity.

Keywords: Prostate cancer, biopsy, power doppler, color doppler, transrectal ultrasound.

INTRODUCTION

Transrectal sonography provides high resolution images of the prostate. Color and power doppler ultrasound (CDUS) further helps in the evaluation of blood

flow through prostatic vessels and has been described as a mean of differentiating malignancy from benign hyperplasia as microvessel density is higher in the former (Sen et al., 2008). Prostate cancers are isoechoic and can be missed by

conventional gray-scale, and not all hypoechoic lesions are malignant (about 70%), CDUS can detect iso-echoic tumors missed by gray-scale TRUS when such tumors are hyper-vascular (**Hilton et al., 2011**).

The aim of the present work was use of color and power doppler in targeting prostatic biopsy and detecting prostate cancer.

PATIENTS AND METHODS

This prospective study included 100 consecutive patients attended Al-Azhar University Hospitals and National Institute of Urology and Nephrology with lower urinary tract symptoms (LUTS), and have fulfilled the inclusion criteria. Informed written consents were obtained from all patients after getting the approval of local ethical committee for the study protocol. Patients were divided into two groups according to PSA levels:

1. Group (A) with PSA level (4.0-10.0) ng /ml(gray zone),and included 69 patients.

2. Group (B) with PSA > 10.0 ng / ml,and included 31 patients.

Inclusion criteria:

- Patients \geq 50 years old with total serum PSA > 4ng/ml.
- Abnormal DRE.
- Hypo-echoic lesions on TRUS.

Exclusion criteria:

- Patients with coagulopathy.
- History of prostate cancer diagnosis or treatment.
- Histological evidence of PIN of any grade.
- Recent urethral instrumentation.

All patients were subjected to full clinical and urological examination including DRE, assessment of the international prostate symptom score (IPSS), complete laboratory investigations (complete urine analysis and culture, serum creatinine, BUN, complete blood count (CBC), coagulation profile, blood sugar level) and prostatic specific antigen (P.S.A.) and pelvic-abdominal ultrasound and TRUS.

Statistical analysis: The data were analyzed using Microsoft Excel 2010 and statistical package for social science (SPSS version 24.0) for windows (SPSSIBM., Chicago, IL). Results were expressed as mean \pm SD with 95% confidence interval using medians for quantitative variables, and using the frequencies and percentage for qualitative ones; a p value < 0.05 was considered statistically significant. Diagnostic parameters of subjects were compared using the independent samples (t) test. Also, Chi-square (χ^2) test were used for comparison of categorical data. Whenever the expected values in one or more of the cells in a 2x2 tables were less than 5, Fisher exact test was used instead and using linear by linear association in larger than 2x2 cross-tables.

RESULTS

The age of group (A) ranged between 50 and 75 years with a mean \pm S.D of 65.7 \pm 6.8 years, while in group (B) ranged between 54 and 84 years with a mean \pm S.D of 69.5 \pm 6.3 years. So, the mean age was higher in group B than group A which was statistically significant (p=0.01).

Digital rectal examination was found 22.6% of group (A) and 40.6% of group

(B) had abnormal DRE which was statistically significant ($p=0.08$).

TRUS revealed hypo-echoic lesions in 40 cases (12 out of them were of group (A), and 28 of group (B)). So, there was no

statistically significant difference in the detection of hypo-echoic lesions between the two study groups (38.7% for group A vs. 40 % for group B) ($p=0.6$ -Table 1).

Table (1): Detection of hypo-echoic lesions in both groups.

Groups		Gray scale U/S		Total	P
		Hypoechoic	No lesion		
Group (A) Gray zone	No.	12	19	31	0.9
	% within Group	38.7%	61.3%	100.0%	
Group (B) Above Gray zone	No.	28	41	69	
	% within Group	40.6%	59.4%	100.0%	
Total	No.	40	60	100	
	% within Group	40.0%	60.0%	100.0%	

Color doppler showed hyper-vascular areas in 51 (51%) patients (15 out of them were of group A and 36 were of group B). However, there was no statistically

significant difference between the groups of the study as regards to the incidence of hyper-vascular lesions ($p=0.7$ - Table 2).

Table (2): Incidence of hyper-vascular lesions on color doppler.

Group		Doppler U/S		Total	P
		Hyper-vascular lesions	No Hyper-vascular lesions		
Group (A)	No.	15	16	31	0.7
	% within Group	48.4%	51.6%	100.0%	
Group (B)	No.	36	33	69	
	% within Group	52.2%	47.8%	100.0%	
Total	No.	51	49	100	
	% within Group	51.0%	49.0%	100.0%	

Histopathological examination of cores taken from hypo-echoic lesions revealed adenocarcinoma in 24 cases (6 out of

them were of group A and 18 were of group B). So, cancer was detected in 50 % (6/12) of hypo-echoic lesions in group A

and in 64.3% (18/28) of group B which was statistically non-significant ($p=0.13-$

Figure 1).

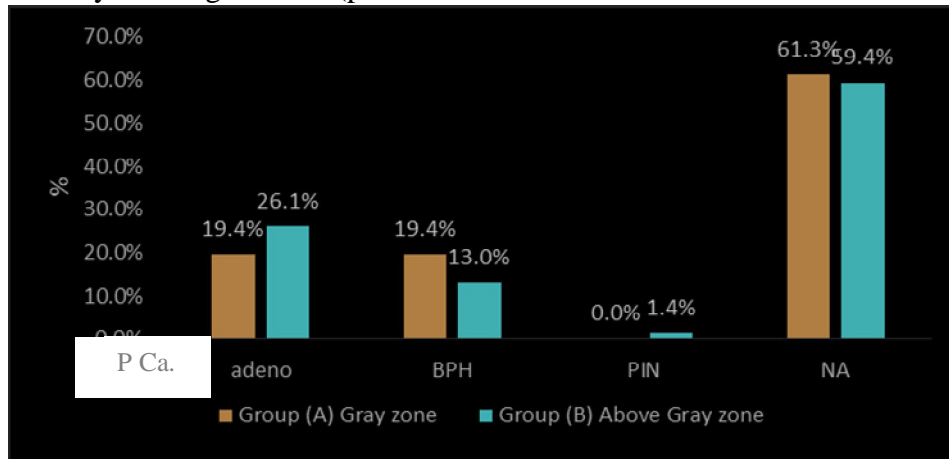


Figure (1): Results of hypo-echoic core histopathology in the study groups.

Comparing between the cores taken from hyper-vascular areas and the results of histopathology revealed that cancer was detected in 38 (74.5%) out of 51 hyper-vascular areas (8 out of them were of group A and 30 were of group B). So, the

incidence of cancer detection in hyper-vascular areas in group B (83.3%) was higher than group A (53.3%) which was statistically significant ($p= 0.02$ -Figure 2).

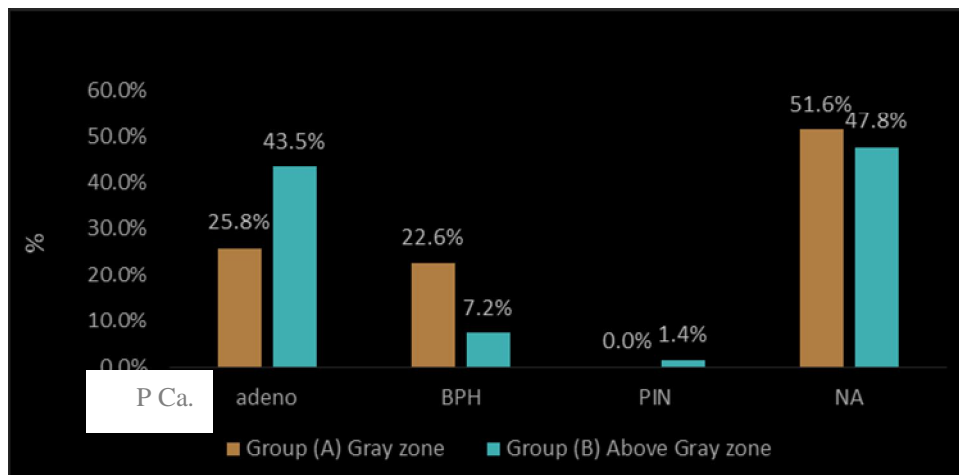


Figure (2): Results of hyper vascular core histopathology in the study groups.

Crosstabulation of gray scale grades and doppler grades depended on histopathology of the lesion:

1. Through this criteria, to start with the patients with hypo-echoic and hyper-vascular lesions crosstabulated with adenocarcinoma, there was a highly significant difference in incidence of adenocarcinoma between hypo echoic hyper-vascular lesions than in hypo-

echoic, non-hyper-vascular lesion according to the histopathology with P-value<0.001(Table 3).

2. There was a highly significant difference in incidence of adenocarcinoma between non-hypo echoic hyper vascular lesions than non-hypo echoic non hyper vascular lesions according to the histopathology (Table 3).

Table (3): Gray scale and doppler cross tabulated with histopathology.

Parameters		Histopathology				P .Value	
		P Ca.	BPH	PIN	Total		
Hypo-echoic	Hyper vascular	No.	19	3	1	23	0.001*
		% within Doppler	82.6%	13%	4.4 %	100.0%	
	Non Hyper Vascular	No.	5	12	0	17	
		% within Doppler	29.4 %	70.6%	0 %	100.0%	
	Total	No.	24	15	1	40	
		% within Doppler	60%	37.5%	2.5 %	100.0%	
Non Hypo-echoic	Hyper vascular	No.	19	9	0	28	0.001*
		% within Doppler	67.9 %	32.1 %	0%	100.0%	
	Non Hyper Vascular	No	3	28	1	32	
		% within Doppler	9.4%	87.5%	3.1%	100.0%	
	Total	No.	22	37	1	60	
		% within Doppler	36.7%	61.7%	1.6%	100.0%	

We found significant different increased in the direction of using the two techniques together (Figure 3).

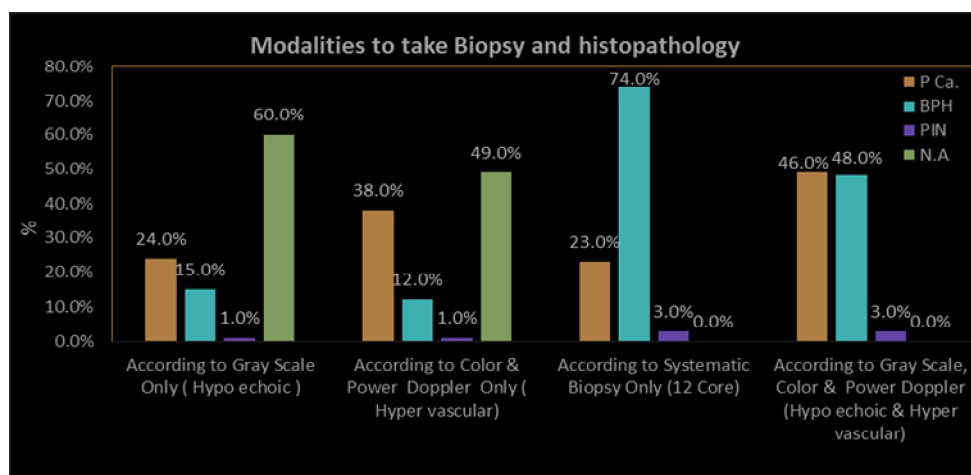


Figure (3): Modalities to take Biopsy and histopathology.

DISCUSSION

Percent free PSA levels correlated significantly with age. Multivariate regression models demonstrated that age and were significant predictors of percent PSA (Crawford, 2013).

Our study showed a highly significant positive correlation between PSA and age in different studied groups. A substantial proportion of prostate cancers detected by DRE at PSA levels less than 4 ng/mL have features associated with clinically aggressive tumors. The omission of DRE from screening protocols might compromise treatment outcomes because many of the cancers detected by DRE alone are potentially curable but may have worse outcomes by the time PSA also reaches a higher level (Onisuruet al., 2007).

Our study confirmed that and showed a highly significant positive correlation between abnormal DRE and prostate cancer in different studied groups, in group (B) incidence of prostate cancer increase with abnormal DRE than group (A).

The most important role for ultrasound in prostate imaging is for biopsy guidance, and TRUS-guided prostate biopsy remains the most commonly used method for confirming the presence of cancer. TRUS has several benefits including safety, portability, low cost, and the ability to perform real-time imaging and image-guided procedures in an office setting (Postema et al., 2015).

The low sensitivity, specificity, positive predictive and negative predictive values of gray scale-B-mode, CDUS represent scant diagnostic performance of these

variables in prostate cancer detection. Prostate cancer detection rates yielded by randomized biopsy were superior than the detection rate of targeted biopsy using B-mode, CDUS as a result, randomized biopsy versus CDUS-targeted biopsies cannot be excluded from biopsy strategy plans for the diagnosis of prostate cancer (Delgado et al., 2016).

Conventional transrectal gray scale ultrasound (GSU) is currently the standard imaging tool for the prostate. GSU is used for volumetry, needle guidance for systematic biopsies and guiding seed placement in brachytherapy. The sensitivity of GSU for prospective tumor detection - varying by experience - has been reported to be up to 60 %. This reflects known sonographic properties of PCa.: approximately 60 % of tumors appear hypo-echoic. Around 35–39 % of tumors are iso-echoic, limiting the detection potential of GSU. The performance reported in the literature varies widely with sensitivities ranging between 8 and 88 % and specificities ranging from 42.5 to 99 % (Loch et al., 2007).

PCa requires angiogenesis to develop into clinically significant disease. The resultant increase in micro-vascular density (MVD) is associated with higher tumor grade and worse prognosis. The increased perfusion in malignant tissue is targeted by doppler ultrasound imaging. Power doppler ultrasound (PDU) is more sensitive but does not depict the direction of flow. PDU can detect flow in vessels as small as 1 mm and therefore allows visualization of a tumor's feeding vessels (Russo et al., 2012).

Twenty-eight percent of all cancers diagnosed were T1c prostate cancer (PCa.) Where the PSA level did not exceed 10 ng/ml and were not visible in the CDUS. Eighty-nine percent of these cancers involved a low-risk of biological recurrence and 86% of the cases of PCa. could benefit from active after the biopsies. Patients with a PSA level not exceeding 10 ng/ml without a DRE anomaly and with a negative CDUS had less than a 5% risk of having a high-risk cancer (**Sauvain et al., 2013**).

During the last years, new imaging techniques have been developed that enable sensitive micro bubble imaging even in the microvasculature, with lower destruction rates. Nowadays, a long list of ultrasound techniques in addition to CDUS (color enhanced ultrasound, ultrasound elastography), multi-parametric magnetic resonance imaging mpMRI and MRI-Transrectal Ultrasound Fusion techniques are available (**Hambrock et al., 2010**).

In our study, grayscale scanning was done for 100 patients from the base of the prostate to the apex, as well as the surrounding structures such as the seminal vesicles, urethra and rectum to look for areas that appear suspicious. This is followed by color doppler and power doppler to assess the flow, through the entire prostate and suspicious foci. The flow signals from color doppler will be evaluated and categorized into hyper-vascular, hypo-vascular lesions and normal vascular areas.

When using gray scale in our study we found 40 (40%) patients with hypo-echoic lesions, 12 (30%) patients in gray zone and 28 (70%) patient above gray

zone, the results of the histopathological examination of the biopsies revealed adenocarcinoma in 24 (60%) patients from total No. of patients with hypoechoic lesions and 24 (24%) patients from total No. of all patients. Six (25%) patients in gray zone and 18 (75%) patients above gray zone. The sensitivity of gray scale in our study 60%, specificity 86.7% PPV (Positive Predictive Value) 75% and NPV (Negative Predictive Value) 76.5%.

The sensitivity of gray scale in our study was 60% which lies in the range found in the literature (8-88%). The specificity was 86.7% which is a near figure to that reported by **Zalesky et al. (2008)**- 85%. The PPV (Positive Predictive Value) was 75%. NPV (Negative Predictive Value) was 76.5% which agree with that mentioned by **Sauvain (2013)** 72% and 79% respectively.

Although gray-scale TRUS was a major achievement in improving the diagnostic yield of prostate cancer especially in cases of non-palpable disease - experience has shown TRUS to have several limitations. The subjective nature of the exam and the expertise of the clinician may affect the interpretation of images. Interpretation of real-time, gray-scale TRUS images is also restricted by limitations of human visual perception.

While using color and power doppler US in our study, we found 51 (51%) patients with hyper-vascular lesions, 15 (29 %) patients in gray zone and 36 (71%) patient above gray zone, the results of the histopathological examination of the biopsies revealed adenocarcinoma in 38 (74.5%) patients from total No. of patients with hyper-vascular lesions and 38 (38%)

patients from total No. of patients. Eight (21%) patients in gray zone and 30 (79%) patients above gray zone.

The sensitivity of color and power Doppler ultrasound in our study 74.5%, specificity 85.7% PPV (Positive Predictive Value) 84.4% and NPV (Negative Predictive Value) 76.4%.

The sensitivity of color and power Doppler ultrasound in our study was 74.5%, which lies in the range reported in the literature (27-92%). The specificity was 85.7% PPV which is nearly similar to that found by **Sauvain (2013)**. The positive predictive value was 84.4% and negative predictive value was 76.4% which is in agreement with **Zalesky et al. (2008)**.

Technical factors may also contribute to the different results when using CDUS for tumor blood flow detection: (1) The limited spatial resolution on color doppler makes it difficult to detect blood flow in very small vessels, (2) low-volume flow results in frequency shifts below the noise level and consequently, cannot be detected and (3) experience of operator.

Definite value can be achieved by using gray scale, color and power doppler ultrasound in imaging and targeting biopsies of the prostate, the hypo-echoic lesions which appeared by gray scale U/S are hyper vascular or non hyper-vascular and hyper-vascular lesions which appeared in color and power doppler ultrasound are hypo-echoic or non hypo-echoic.

So, we have four characters for prostate:

1. Hypo-echoic hyper-vascular lesions (23 patients).

2- Hypo-echoic, nonhyper-vascular lesions (17 patients).

3- Hyper-vascular, nonhypo-echoic lesions (28 patients).

4- Non hypo-echoic, non hyper-vascular prostate (32 patients).

When using gray scale and doppler ultrasound in our study, we found 67 (67%) patients have a lesion which has one or two characters either hypo-echoic and hyper-vascular or hypo-echoic only or hyper-vascular only. The results of the histopathological examination of the biopsies revealed adenocarcinoma in 43 (64.2%) patients from No. of patients with lesions and 43 (43%) patients from total No. of patients. Eleven (24%) patients in gray zone and 35 (76%) patients above gray zone. The incidence of prostatic adenocarcinoma in lesions which have the two characters hypo-echoic, hyper-vascular 19 patients from 23 patients (82.6%). The sensitivity of gray scale and doppler together in our study 98%, specificity 71.7% PPV (Positive Predictive Value) 69.7% and NPV (Negative Predictive Value) 95.2%.

So, we recommend using the two modalities, gray scale and doppler in targeting prostatic biopsies and once hypo-echoic, hyper-vascular lesions appeared, biopsy should be taken.

CONCLUSION

The combination of color and power doppler ultrasound and gray-scale TRUS increased the sensitivity of detecting prostate cancer while not decreasing the specificity. Lesions with positive color and power doppler ultrasound findings and negative gray-scale imaging results may be significant cancers. The use of

color and power doppler ultrasound may require skills, but it can easily be practiced by activating it during normal TRUS.

REFERENCES

1. **Crawford D. (2013):** Epidemiology of prostate cancer, *J. Urology*, 62 (6): 3–12.
2. **Delgado O., Arlandis S., Guzman M., Bonillo G., Broseta R. and Boronat Tormo, F. (2016):** Diagnostic performance of power doppler and ultrasound contrast agents in early imaging-based diagnosis of organ-confined prostate cancer: Is it possible to spare cores with contrast-guided biopsy? *J. of Radiology*, 85 (10): 1778–1785.
3. **Hambroek T., Somford DM. and Hoeks C. (2010):** Magnetic resonance imaging guided prostate biopsy in men with repeat negative biopsies and increased prostate specific antigen. *J Urol.*, 183:520–527.
4. **Hilton W., Padalecki S., Ankerst D., Leach R., Ilic D., O'Connor D., Green S. and Wilt T. (2011):** Screening for prostate cancer: an updated Cochrane systematic review. *BJU International*. 91(107): 882-886.
5. **Loch T., Loch A. and Grabski B. (2007):** Computerized transrectal ultrasound (C-TRUS) of the prostate: detection of cancer in patients with multiple negative systematic random biopsies. *World J. Urol.*, 25:375–380.
6. **Onisuru T., Kimberly O., Roehl A., Misop H., Stacy L., Sara N., Gashti W. and Catalona J. (2007):** Characteristics of prostate cancer detected by digital rectal examination only, *European Urology*. 70 (6): 1117–1120.
7. **Postema A., Mischi M. and Rosette J. (2015):** Multiparametric ultrasound in the detection of prostate cancer: a systematic review, *World J Urol.*, 33:1651–1659
8. **Russo G., Mischi M. and Scheepens W. (2012):** Angiogenesis in prostate cancer: onset, progression and imaging, *BJU Int.*, 110 (11):794-808
9. **Sauvain E., Sauvain P., Rohmer D., Louis N., Nader R., Papavero J., Bremon M. and Jehl J. (2013):** Value of transrectal power Doppler sonography in the detection of low-risk prostate cancers, *Diagnostic and Interventional Imaging*. *Int.J. of Radiology*, 94(1): 60–67
10. **Sen J., Choudhary L., Marwah S., Godara R., Marwah N. and Sen R. (2008):** Role of Color Doppler Imaging in Detecting Prostate Cancer. *Asian J. of Surg.*, 31 (1): 16-19.
11. **Zalesky M., Urban M. and Smerhovsk Z. (2008):** Value of power Doppler sonography with 3D reconstruction in preoperative diagnostics of extraprostatic tumor extension in clinically localized prostate cancer. *Int J Urol.*, 15:68–75.

هل يزيد استخدام الموجات الصوتية بالدوبلر الملون والمقوى من معدلات إكتشاف سرطان البروستاتا ؟

عزمي محمد أحمد عمر* - شحاتة حسن فرغل** - شوقي عبد العظيم المكاوي**
خالد فتحي عليوة*

*المعهد القومي للكلى والمسالك البولية بالقاهرة.
**قسم جراحة المسالك البولية بكلية طب الأزهر بالقاهرة

خلفية البحث : بالرغم من أن الموجات الصوتية العادية (الرمادية) تعتبر إنجازاً حقيقياً في إكتشاف سرطان البروستاتا ، إلا أنه لا زال ذوى الخبرة بالموجات الصوتية العادية (الرمادية) لا يستطيعون التمييز بين الصور والتي لها أكثر من 32 مستوى من مستويات الموجات الصوتية العادية (الرمادية) من جملة 256 من صور الموجات الصوتية الرمادية.

الهدف من البحث: استخدام الدوبلر الملون والمقوى في إستهداف عينات البروستاتا وإكتشاف سرطان البروستاتا.

المرضى وطرق البحث : هذه الدراسة تشمل ١٠٠ مريض من المرضى القاصدين مستشفيات جامعة الأزهر والمعهد القومي للكلى والمسالك بالقاهرة، والذين يعانون من أعراض الجهاز البولي السفلي، والذين لديهم إرتفاع فى نسبة دلالات أورام البروستاتا أو نتائج الفحص الشرجى للبروستاتا غير طبيعى . وقد تم إستثناء من لديهم خلل فى سيولة الدم وكذلك من سبق تشخيصهم بوجود مرض سرطان البروستاتا لديهم . وفي هذه الدراسة تم إجراء فحص جميع أجزاء البروستاتا بالموجات فوق الصوتية العادية (الرمادية) والأجزاء المحيطة وذلك بحثاً عن أي بؤر سرطانية متوقعة، متبوعاً بفحص البروستاتا بالدوبلر الملون والمقوى لتقييم تدفق الدم داخل البروستاتا أو زيادة تدفق الدم في بؤر معينة بداخلها وتم أخذ عينات من البروستاتا من البؤر ذات الإمداد الدموي الغزير والبؤر الناقصة الصدى إسترشاداً بالموجات فوق الصوتية.

النتائج : بعد تحليل الأنسجة من عينات البؤر ناقصة الصدى تبين وجود سرطان البروستاتا في ٢٤ (٦٠٪) مريض من عدد المرضى الذين لديهم بؤر ناقصة الصدى وبالتالي يمثلون ٢٤ (٢٤٪) من العدد الإجمالي لمرضى الدراسة : منهم 12/6 (50٪) مرضى في المجموعة (أ) و 28/18 (64,3٪) من المجموعة (ب) . وبعد تحليل الأنسجة من عينات البؤر ذات الإمداد الدموي الغزير تبين وجود سرطان البروستاتا فى ٣٨ (74,5٪) مريض من إجمالي عدد المرضى الذين لديهم بؤر ذات إمداد دموي غزير وهم يمثلوا ٣٨ من العدد الكلى للمرضى محل الدراسة منهم 53,3٪ مريض في المجموعة (أ) و 83,3٪ مريض في المجموعة (ب).

الإستنتاج: استخدام الموجات فوق الصوتية العادية مع الدوبلر الملون المقوى في إستهداف عينات البروستاتا يزيد من حساسية إكتشاف سرطان البروستاتا بينما لا يقلل من النوعية.