

# EVALUATION OF THE EFFECT OF ARGON LASER IN TREATMENT OF RESISTANT INFECTIVE CORNEAL ULCER

By

**Ahmed Samy El-Behiry, Hassan El-Sayed El-Baz and Hassan Metwally  
Bayoumy**

Department of Ophthalmology, Faculty of Medicine, Al-Azhar University

**Corresponding author:** Ahmed Samy El-Behiry,

**E-mail:** [samyahmdsamy57@gmail.com](mailto:samyahmdsamy57@gmail.com)

## ABSTRACT

**Background:** Resistant infective corneal ulcer is an ocular emergency which needs an early and aggressive management to avoid its serious complications. Despite the availability of a wide range of newer antimicrobials, new diagnostic techniques and recent treatment modalities, infective keratitis continues to pose a diagnostic and therapeutic challenge.

**Objective:** To evaluate the effectiveness and safety of the use of the argon laser in treatment of cases with resistant infective corneal ulcers.

**Patients and methods:** Thirty patients with different forms of resistant infected corneal ulcers included in this study attended the cornea unit in the Ophthalmology Department at Al-Azhar University Hospitals. The cases were treated with argon laser, during the period from May 2019 to August 2020. We followed up the cases to detect the response to the argon laser until complete healing was achieved. Each case was followed up for 3 months to detect any relapse or recurrence.

**Results:** We found that 86.6 % of cases healed without relapse (56.6 % of cases healed after about 2 weeks from laser therapy, 13.3 % healed after about 3 weeks, and 16.6 % healed after about 4 weeks), while 13.3 % of cases healed with relapse. Amniotic membrane grafting was needed in 13.3 % of cases.

**Conclusion:** Argon laser, in most of cases, led to complete healing with small corneal opacity.

**Keywords:** Argon laser photocoagulation, resistant infective corneal ulcers.

## INTRODUCTION

There is no doubt that infective corneal ulcer is a challenging disease facing ophthalmologists in every day clinic. It is considered a major cause of vision loss and second cause of monocular blindness in some developing countries in the tropic especially in Egypt (*Saad-Hussein et al., 2011*). A lot of micro-organisms cause infective corneal ulcer. Among them are

bacteria, fungi, viruses, protozoa, and chlamydia (*Basak et al., 2010*).

There are several lines of treatment according to the causative agent e.g: therapeutic drugs such as topical anti-viral, anti-fungal, fortified antibiotic, bandage soft contact lens and amniotic membrane. Limbal stem cell transplantation is also used to promote healing of epithelial defect but complete healing takes anywhere from about a few

weeks to several months (*Fila et al., 2017*).

A new technique with the use of argon laser irradiation of refractory fungal keratitis has proved beneficial in the treatment of resistant infected corneal ulcers as an adjunctive treatment (*Pellegrino and Carrasco, 2013*).

Argon laser has been applied in the cornea to treat corneal neovascularization and lipid keratopathy (*Anand et al., 2019*).

Argon laser causes heating and denaturation leading to cell death and coagulation. Fluorescein dye can absorb argon laser when staining the corneal epithelial defect resulting in its thermal damaging effect. Over-heating of the corneal tissues produces inhibition of cellular enzymes (40°C-45°C), and damage of cellular proteins (above 60°C) and DNA (above 70°C). This damage affects both the host tissue and the organ itself (*Wagdy et al., 2020*).

**The aim of this work was to** evaluate the effectiveness and safety of the use of argon laser in treatment of cases with resistant infective corneal ulcers.

## PATIENTS AND METHODS

This study was conducted in Ophthalmology Department at Al Hussein University Hospital, Faculty of Medicine, Al-Azhar University.

Thirty patients with different forms of resistant infected corneal ulcers included in this study. They were treated with argon laser when no obvious improvement was achieved after receiving the specific treatment according to culture and sensitivity. Patients were recruited from the corneal specialty clinic of Al-Azhar

University Hospitals in the period from May 2019 to August 2020. Approval for the study was obtained from the hospital's ethical committee. All patients received a thorough explanation of the study design and aims, and provided written informed consents.

**Inclusion criteria:** Cases with corneal ulcers resistant to medical treatment after 3 weeks of continuous specific treatment.

**Exclusion criteria:** Corneal thinning (less than 300µm), autoimmune disease, known or suspicious glaucomatous eye or ocular hypertension, and uncooperative patient.

An approval of the study was obtained from Al- Azhar University academic and ethical committee. Every patient signed an informed written consent for acceptance of the operation.

**Intervention and outcome measures:** After meeting all inclusion criteria, the patients were evaluated by Full history taking, complete clinical evaluation including (history taking with stress on glaucoma), complete ophthalmic examination including (visual acuity, eyelid and palpebral fissure: to exclude: trichiasis, lagophthalmos and lid margin irregularities and inflammations, conjunctiva and sclera were examined for ciliary and conjunctival injection, exposure, dryness, and chronic inflammation, and lacrimal sac for exclusion of dacryocystitis as a source of infection. Slit-lamp biomicroscopy, corneal scraping from the ulcer bed and edges for culture and sensitivity test).

Antimicrobial drugs were given to all cases depending on clinical suspicion and the culture results, and modification of the

antimicrobial drugs according to the culture and sensitivity results.

Previous medical treatment was stopped for 24 hours, and conservative nonspecific treatment was giving in the form of topical cycloplegic and lubricant drops.

Daily follow-up for 1 week was done in all cases regarding the size of the ulcer in tridimensional measures, depth of the ulcer, surrounding edema and infiltration, anterior chamber reaction, and level of hypopyon if present.

When no noticeable improvement was achieved after 3 weeks, the ulcer was considered resistant to specific treatment and argon laser therapy was tried as an adjunctive treatment to the usual corneal ulcer treatment including both specific and nonspecific measures.

#### **Argon laser treatment procedure:**

Before laser treatment, the eye was medicated with benoxinate hydrochloride 0.4% as surface anesthesia. A single drop of fluorescein sodium 0.25% was instilled in order to stain the corneal epithelial defect to allow the for-argon laser energy to be absorbed by the stained corneal. Argon laser irradiation was performed using argon green wavelength (Carl Zeiss LSL 532s AG; Carl Zeiss Meditec AG, Jena, Germany). Argon laser beam parameters were spot size of 500  $\mu\text{m}$ ,

pulse duration of 0.2 seconds, and power of 900 MW. The argon laser beam was focused on the stained corneal epithelial defect and when triggered we noticed blanching of the corneal stroma and small cavitations that may have reached the middle stroma (honey comb appearance) occur. The total area of epithelial defect was covered with argon laser shots in one session. These laser shots were triggered towards the corneal epithelial defect side by side to cover the whole area.

Follow up of the cases for the Criteria of healing included decrease in size of epithelial defect, decrease in area and density of stromal infiltrate, cleaning of the base of ulcer, decrease in the surrounding corneal edema, decreased level of hypopyon, scar formation, and beginning of vascularization, each case was followed up for 3 months to detect any relapse or recurrence.

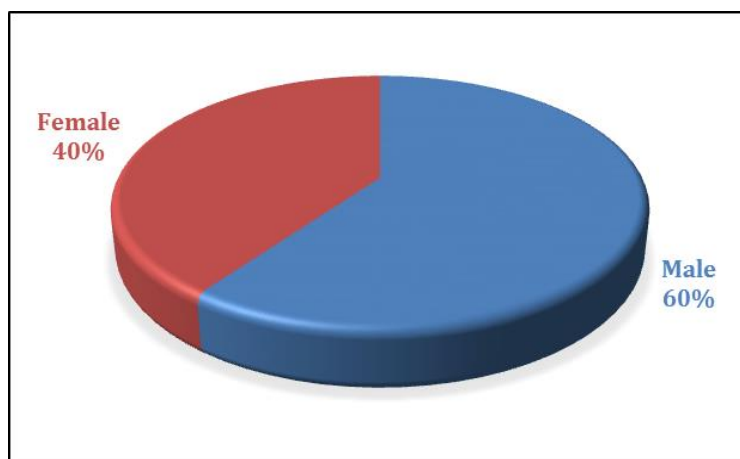
#### **Statistical analysis:**

Data were analyzed using Statistical package for the Social Science (SPSS) version 16.0. Quantitative data were expressed as mean. Qualitative data were expressed as frequency and percentage and were compared by. Chi-square test was done. P-value  $< 0.05$  was considered as significant.

## RESULTS

The age of cases ranged from 10 to 74 years, with the mean age of 43 years old. Sex distribution revealed that 18 cases

(60%) were males, while 12 cases (40%) were females (**Figure 1**).



**Figure (1): Sex distribution of 30 cases of corneal ulcers**

As regarding socioeconomic state 24 cases (80%) were rural while 6 cases (20%) were urban. As regarding occupation 13 cases (43.3 %) were farmer.

There were 17 cases as (students, housewives, employers, and workers) (56.6%) (**Table 1**).

**Table (1): Socioeconomic state and Occupational state of 30 cases of corneal ulcers**

Residence	Rural		Urban		Total	
	No	%	No	%	No	%
	24	80	6	20	30	100
P. value	0.002					
Occupation	No				%	
Farmer	13				43.7	
Others:	17				56.6	
Student	3				10	
Housewife	7				23.3	
Employee	2				6.7	
Worker	5				16.7	
P	0.035					

As regarding risk factors for ulcer they were present in 26 cases (86.6%), and we had 4 cases (13.3%) with no definite risk factors. It was found that ocular trauma (mainly of plant origin, F.B. or insect) was the most frequent risk factor as it occurred

in 15 cases (50%) followed by contact lens wearers in 6 cases (20%) (4 cases (13.3%) with cosmetic C.L. and 2 cases (6.6%) with refractive C.L). Diabetic patients were 5 cases (16.6 %) (**Table 3**).

**Table (3): Risk factors of corneal ulcers**

Risk factors		No (26)	%
Contact lens wearer (CL) No = 6	Cosmetic	4	13.3
	Refractive	2	6.7
Trauma No = 15	Plant	11	36.7
	Insect	1	3.3
	Corneal foreign body (FB)	3	10
Diabetes mellitus (DM)		5	16.7
Unidentified risk factor		4	13.3
Total		30	100
P. value		0.091	

As regarding culture results we observed that the mycotic ulcers were the main causes of resistant corneal ulcer occurred in 13 cases (43.3%), bacterial

organisms occurred in 10 cases (33.3%) and acanthamoeba in 2 cases (6.6 %). On the other hand, 5 cases (16.6 %) gave negative culture result (**Table 4**).

**Table (4): Culture results of 30 cases of corneal ulcers**

Type of growth and the isolated organism		No (30)	%
Fungal growth	Asp. Flavus	5	16.7
	Fusariumsolani	3	10
	Asp. Fumigatus	2	6.7
	Candidaalbicans	1	3.3
	Cladosporium	1	3.3
	Asp. Niger	1	3.3
	Total	13	43.3
Bacterial growth	Pseudomonas. A	4	13.3
	Staph. Aureus	3	10.0
	Klebsiella	1	3.3
	E. coli	1	3.3
	Staphepidermides	1	3.3
	Total	10	33.3
Acanthamoeba		2	6.6
No growth		5	16.7
Total cases		30	100

As regarding percentage and duration of healing of resistant corneal ulcers after argon laser treatment healing was achieved after about 2 weeks in 17 cases

(56.6%), in 4 cases (13.3%) after about 3 weeks, and after about 4 weeks in 5 cases (16.6%) (**Table 5**).

**Table (5): Percentage and duration of healing of resistant corneal ulcers after laser treatment**

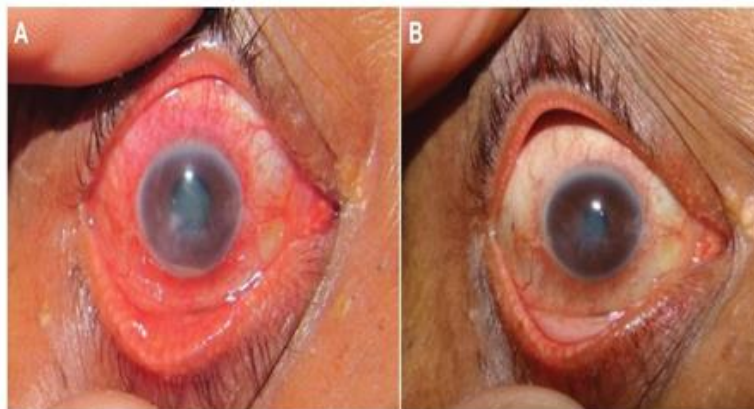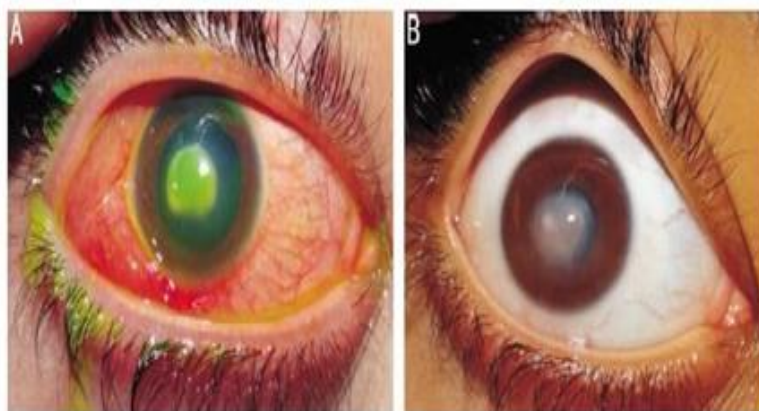
Duration of argon laser	No and Percentage
2 weeks	17 (56.6 %)
3 weeks	4 (13.3 %)
4 weeks	5 (16.6 %)

Effect of argon laser on visual acuity improvement: Visual acuity improvement was achieved in 17 cases (56.6%) with a gain of one line in 9 cases (30%) and with

a gain of two lines or more in 8 cases (26.6 %), while no visual acuity improvement in 13 cases (43.3 %) (Table 6).

**Table (6): Visual acuity improvement in cases treated by argon laser**

Visual acuity	No, & Percentage
No improvement	13 (43.3%)
Gain of one line	9 (30%)
Gain of two or more lines	8 (26.7%)

**Case 1:****Figure (2): Resistant corneal ulcer associated with hypopyon before (A) and after (B) argon laser adjunctive therapy****Case 2:****Figure (3): Resistant mycotic corneal ulcer associated with hypopyon before (A) and after (B) argon laser adjunctive therapy (healing was achieved after 4 wk).**

## DISCUSSION

Corneal ulcer is considered an ophthalmologic emergency, as it is sight threatening condition. It may be sterile but it is often microbial in origin; bacterial, fungal, viral, or parasitic (7). To the best of knowledge, there are no reports or retrograde studies that have investigated the treatment of resistant corneal ulcers with argon laser in humans. *Fila et al. (2017)* reported the treatment of *Pseudomonas keratitis* in rabbit corneas by using argon laser.

Regarding age distribution, this study revealed that the age ranged from 10 years to 74 years with the majority of cases above 40 years (72 %). This agreed with the study carried out by *Sahay et al. (2019)* who recorded an age incidence between 12 and 65 years (peak affection was during the fourth decade).

In contrast there was study done by *Maung et al. (2012)* in which the majority of the cases were between 11 – 40 years, as in this area large number of population work in agriculture field and the young adults and middle-aged people are the main workers there.

Regarding sex distribution, there was higher incidence in the males (60%) than females (40%); this result was in agreement with the study carried out by *Mandour et al. (2016)* who studied 40 cases of resistant corneal ulcers with male to female ratio 9:1. Also in another study done by *Derek et al. (2010)* the males were (70.6 %) of the cases of the study. These results can be explained by outdoor activities of males relative to females in our Arab community.

Regarding the residency of the corneal ulcer's cases, this study revealed that the majority of cases were living in rural area (80 %), and the majority of the cases were farmers (43.3 %). These results agreed with study carried out by *Titiyal et al. (2013)* in which (53 %) of the complicated cases were living in rural area versus only (42 %) of the healed cases living in urban area. This result can be explained by increasing the risk of exposure to trauma due to outdoors activities, the poverty and bad compliance to the treatment by the patients in the communities of the study.

In our study, ocular trauma was the main risk factor for resistant corneal ulcer as 50% gave history of different types of trauma. For example, Trauma of plant origin occurred in (36.6 %) of cases, after removal of metallic F.B occurred in (10%) of cases. Next to trauma, comes contact lens wear (20%) then diabetes mellitus (16.6 %). Also, in this study, it was observed that patients who gave history of trauma of plant origin were 36.6% mainly suffering from mycotic infection. In contrast the patients, who gave history of metallic F.B 10%, were suffering from bacterial ulcers mainly *staphylococcus aureus*. These results agreed with *Mandour et al. (2016)* who observed that majority of cases in their study gave history of trauma, 63% were trauma of plant origin, and 25% metallic corneal F.B. In contrast, *Bou et al. (2019)* reported that contact lenses were the main risk factors in 46 % of cases while ocular trauma was in 8%.

As regards to culture results in this study, we observed that the mycotic ulcers were the main causes of the resistant corneal ulcer occurred in 43.3%, bacterial

organisms occurred in 33.3% and acanthamoeba in 6.6 %. On the other hand, 16.6% gave negative culture result. These results were in agreement with *Mohammad et al. (2016)* who recorded that 48% of the cases give fungal results, 20% bacterial, and 32% were culture negative.

As regards healing of ulcers, it was found that, when the laser therapy procedure was combined with the specific antimicrobial agents according to the culture and sensitivity test results, the duration of treatment was obviously shortened and this can be considered a good result. Complete healing was achieved in (86.6 %) of cases treated by laser in a period ranging from 2–4 weeks without the need for other adjunctive procedures. These results were coincided with the results of *Khater (2016)* who compared the effect of argon laser with intra-stromal voriconazol injection in mycotic keratitis, reporting that complete healing was achieved in 90% of cases in argon laser group (18cases) in a duration ranged from about 2 to 4 weeks. While in the other group treated with intra-stromal voriconazol injection, healing was achieved only in 80% of cases and in a longer duration ranged from 2 to 6 weeks.

As regards the visual acuity results, 56.6% of cases were improved with one or more line gain (decimal system), and 43.3% did not show any improvement after treatment by laser. This was in agreement with *Khater (2016)* study where 45% of cases treated with argon laser with no any improvement.

In contrast, a study done by *Ghanem et al. (2019)* reported that visual acuity results were insignificant when comparing

argon laser treatment to amniotic membrane graft with tissue debridement in mycotic keratitis.

As regards fate of corneal ulcers, it was found that after argon laser treatment, only 13.3% needed amniotic membrane grafting to achieve complete healing. The same results were reported in *Khater (2016)* study in which amniotic membrane graft was needed for 10% cases of argon laser treated.

The end results of the ulcer cases reported that single bacterial organism ulcers have better prognosis than fungal and multi- bacterial ulcers. These results were in agreement with the study carried out by *Titiyal et al. (2013)* in which single bacterial organism ulcers have a better prognosis than fungal ulcers and mixed organisms' ulcers. These results and ours may be due to delay in giving anti-fungal therapies comparing to antibiotics, in addition the fungi are highly virulent and pathogenic.

In our study, we did not face any complications of treatment by argon laser.

## CONCLUSION

Argon laser can be used as a last resort modality after failure of antimicrobial drugs in the treatment of resistant infective corneal ulcers. Also, Argon laser was safe on the cornea and other ocular structures when applied directly to the ulcer with the same parameters used in this study.

## REFERENCES

1. **Anand N, Reidy JJ and Riaz KM. (2019):** Short-term regression of corneal neovascularization with combination therapy of argon green laser photocoagulation and



- subconjunctival bevacizumab. *International Medical Case Reports Journal*, 12: 89-94.
2. **Basak KS, Basak S, Mohanta A and Bhowmick A. (2010):** Epidemiological and microbiological diagnosis of suppurative keratitis in Gangetic West Bengal, Eastern India. *Indian J Ophthalmol.*, 53:17-22.
  3. **Bou KJ, Siew TT, Ter Wei C and Mun TL. (2019):** Infectious keratitis: findings from a retrospective review in the central zone of Sarawak. *Malaysian Journal of Ophthalmology*, 1(3): 181-196.
  4. **Derek YK, Savitri S, Prashant G, Usha G, David M and Gullapalli NR. (2010):** Corneal ulceration in the elderly in Hyderabad, south India. *Br J Ophthalmol.*, 84(1): 54-9.
  5. **Fila G, Kawiak A and Grinholc MS. (2017):** Blue light treatment of *Pseudomonas aeruginosa*: Strong bactericidal activity, synergism with antibiotics and inactivation of virulence factors. *Virulence*, 8(6): 938-58.
  6. **Ghanem R, Ghanem M and Azar D. (2019):** LASIK complications and their management. *Refractive surgery*. 3rd ed. Pbl. Philadelphia: Elsevier Mosby, Pp. 221-48.
  7. **Khater MM. (2016):** Argon laser photocoagulation versus intrastromal voriconazole injection in treatment of mycotic keratitis. *Int J Ophthalmol.*, 6: 225-9.
  8. **Mandour SS, Marey HM and Farahat HG. (2016):** Resistant microbial keratitis in South Nile Delta, Egypt: Influence of regional risk factors. In *Seminars in Ophthalmology*, 31(5):473-8.
  9. **Maung N, Thant CC, Srinivasan M, Upadhyay MP, Priyadarsini B and Mahalakshmi N. (2012):** Corneal ulceration in South East Asia. II: A strategy for the prevention of fungal keratitis at the villagelevel in Burma. *Br J Ophthalmol.*, 90(8): 968-70.
  10. **Mohammad M, Mohammad S and Adel A. (2016):** Argon laser photocoagulation versus intrastromal voriconazole injection in treatment of mycotic keratitis, *Int J Ophthalmol.*, 9(2): 225-9.
  11. **Pellegrino F and Carrasco MA. (2013):** Argon laser phototherapy in the treatment of refractory fungal keratitis, *Cornea*, 32(1):95-7.
  12. **Saad-Hussein A, El-Mofty HM and Hassanien MA. (2011):** Climate change and predicted trend of fungal keratitis in Egypt. *East Mediterr Health J.*, 17: 468-73.
  13. **Sahay P, Singhal D, Nagpal R, Maharana PK, Farid M and Gelman R. (2019):** Pharmacologic therapy of mycotic keratitis. *Survey of Ophthalmology*, 64(3): 380-400.
  14. **Titiyal JS, Negi S, Anand A, Tandon R, Sharma N and Vajpayee RB. (2013):** Risk factors for perforation in microbial corneal ulcers in north India. *Br J Ophthalmol.*, 90(6): 686-9.
  15. **Wagdy FM, Sarahan AR, Atta GM and Aziz MS. (2020):** Riboflavin and fluorescein stain before argon laser in the treatment of resistant corneal ulcer. *Menoufia Medical Journal*, 33(4): 1167.

## تقييم دور الأرجون ليزر في علاج قرحة القرنية المعدية المستعصية

أحمد سامي البحيري، حسن السيد الباز، حسن متولى بيومى

قسم طب وجراحة العيون، كلية الطب، جامعة الأزهر

E-mail: [samyahmdsamy57@gmail.com](mailto:samyahmdsamy57@gmail.com)

**خلفية البحث:** قرحة القرنية المعدية المستعصية هي حالة طارئة للعين تحتاج إلى عناية مبكرة وحازمة لتجنب مضاعفاتها الخطيرة. وعلى الرغم من توافر مجموعة واسعة من مضادات الميكروبات الحديثة، وتقنيات التشخيص الجديدة وطرق العلاج الحديثة، لا يزال التهاب القرنية المعدية يشكل تحديًا تشخيصيًا وعلاجيًا. هنالك أمل جديد للعلاج باستخدام شعاع الأرجون ليزر في حالات قرحة القرنية المستعصية بجانب العلاج الدوائي المحدد.

**الهدف من البحث:** تقييم فعالية وسلامة استخدام ليزر الأرجون في علاج حالات قرح القرنية المعدية المستعصية.

**المرضى وطرق البحث:** ثلاثون مريضاً يعانون من أشكال مختلفة من قرحة القرنية المصابة المستعصية المتضمنة في هذه الدراسة حضروا وحدة القرنية في قسم طب وجراحة العيون في مستشفيات جامعة الأزهر. تم علاج 30 حالة بليزر الأرجون، خلال الفترة من مايو 2019 إلى أغسطس 2020. وقمنا بمتابعة الحالات للكشف عن الاستجابة لليزر الأرجون حتى إكمال الشفاء. ثم تمت متابعة كل حالة لمدة 3 أشهر للكشف عن أي إنتكاس أو تكرار.

**نتائج البحث:** وجدنا أن 86.6% من الحالات شُفيت دون إنتكاس (56.6% شُفيت بعد حوالي أسبوعين من العلاج بالليزر، و 13.3% شُفيت بعد حوالي 3 أسابيع، و 16.6% شُفيت بعد حوالي 4 أسابيع)، بينما شُفيت 13.3% من الحالات مع الانتكاس. وقد كان هناك حاجة لتطعيم الغشاء الذي يحيط بالجنين في 13.3% من الحالات.

**الاستنتاج:** ليزر الأرجون، في معظم الحالات، يؤدي إلى الشفاء التام مع عتامة القرنية الصغيرة.

**الكلمات الدالة:** شعاع الأرجون ليزر، قرحة القرنية المعدية المستعصية.